

CENTINEL
SPINE®

PRODISC® L

Modular Intervertebral Disc Prosthesis
for Stabilizing the Lumbar Spine
and Restoring the Physiological Range
of Motion.



SURGICAL TECHNIQUE

 Image intensifier control

Warning

This description alone does not provide sufficient background for direct use of Centinel Spine products. Instruction by a surgeon experienced in handling these products is mandatory.

Processing, Reprocessing, Care and Maintenance

For general guidelines, function control and dismantling of multi-part instruments, please contact your local sales representative or refer to: http://www.centinelspine.com/prodisc_reprocessing.html
For general information about reprocessing, care and maintenance of Centinel Spine reusable devices, instrument trays and cases, please consult the Important Information leaflet (SE_023827) or refer to: www.centinelspine.com/prodisc_reprocessing.html

TABLE OF CONTENTS

INTRODUCTION	prodisc L	2
	Indications and Contraindications	4
	Kinematics	5
	Implants	7
	Instruments	9
	Optional Instruments	16
	Other Centinel Spine Products for Access, Discectomy and Endplate Preparation	19
	Preoperative Planning	21
	Surgical Technique	22
	Cases	30

BIBLIOGRAPHY		33
--------------	--	----

prodisc L

Proven concept from the field of joint endoprosthetics

Extensive experience

- Developed as a result of decades of experience in knee and hip prosthetics
- Over 15,000 implanted prodisc L prostheses since 1990
- Polyethylene inlays in conjunction with cobalt-chromium-molybdenum plates have been in clinical use in knee, hip and spinal prosthetics for several decades

Motion preservation

- Retention of the physiological range of motion for flexion/extension, rotation and lateral inclination
- Restoration of the height of the relevant segment, anatomical balance, and the stability of the spinal column
- Guided and controlled motion potentially limits the load on facet joints

Good anatomical fit

- The size of the implant, the lordosis angle and the height of the prosthesis can be interchanged to suit patient anatomy
- Anatomical design of the implant plates

Fixation

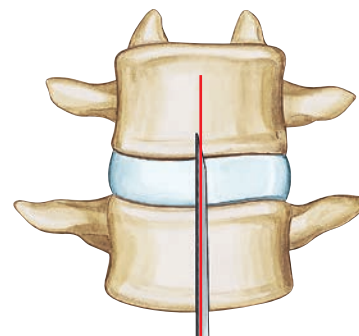
- Central keels and spikes provide primary fixation
- Porous titanium-coated implant plates potentially allow for osteointegration



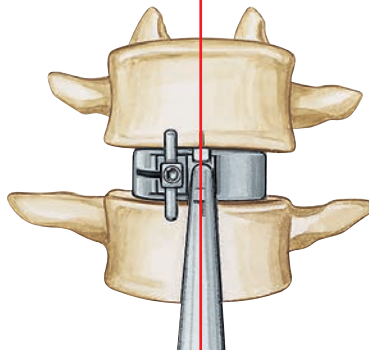
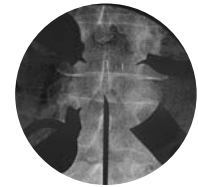Minimally invasive access

The instruments:

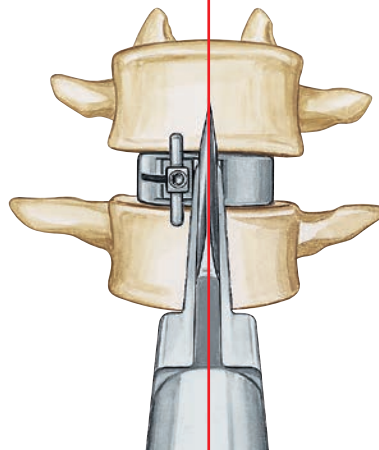
- Narrow, indicated instruments allow short, minimally invasive surgery and therefore earlier patient mobilization
- Trial implants with adjustable stop to prevent excessive posterior positioning
- The keel bed is prepared while the chisel is guided over the trial implant
- The implant is guided into proper position via the chisel cut
- Orientation at the midline for precise implanting



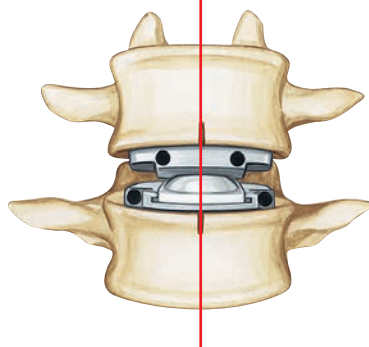
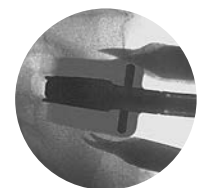
Mark the midline



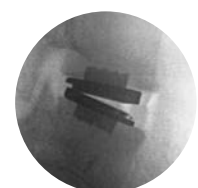Insert the trial implant



Chisel the keel bed guided over the trial implant



Final position of the implant



INDICATIONS AND CONTRAINDICATIONS

prodisc L implants are used to replace a lumbar intervertebral disc and to restore disc height and segmental motion.

Indications

Lumbar discopathy

Contraindications

- Spinal stenosis, radiculopathy
- Increased segmental instability
- Spinal deformities, spondylolisthesis above 25%
- Radiographic confirmation of severe facet joint disease or degeneration
- Osteoporosis, osteochondrosis, and severe osteopenia
- Acute or chronic systemic, spinal, or localized infections
- Systemic and metabolic diseases
- Any medical and surgical conditions precluding the potential benefit of spinal surgery
- Foreign body sensitivity to the implant materials
- Dependency on pharmaceutical drugs, drug abuse, or alcoholism
- Pregnancy
- Obesity
- Lack of patient cooperation

Patient exclusion recommendations

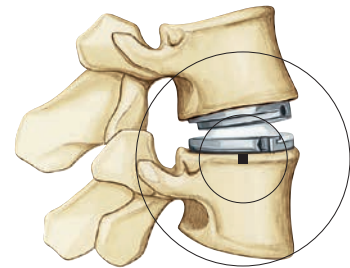
Patient selection is one of the most important factors contributing to the outcome of the total disc replacement procedure. The following may affect clinical outcomes:

- A condition of senility or mental illness, alcoholism or smoking
- Dependency on pharmaceutical drugs or drug abuse
- The patient's occupation or activity level
- Compromised vertebral bodies at affected level due to current or past trauma (fractures)
- Substantial loss of disc height, where applied segmental distraction may lead to damage of the great vessels
- Involved vertebral endplate dimensionally smaller than the minimum implant footprint size in both the medial-lateral and the anteriorposterior directions
- Severe abnormality of the endplate (e.g. large Schmorl nodes)
- Posterior spinal defect (e.g. Pars defect)

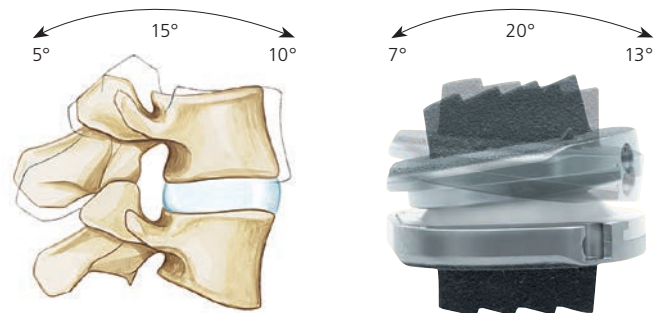
KINEMATICS

The kinematics correspond to the physiological conditions in the vertebral joints¹:

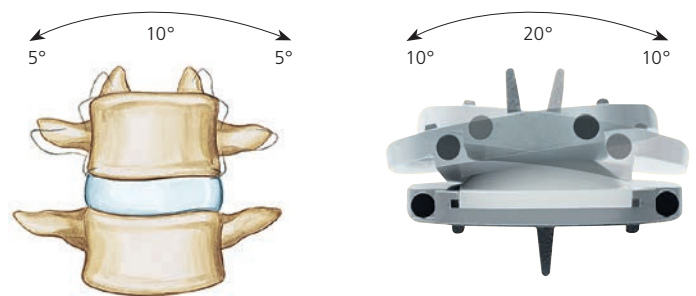
The rotational center is just below the superior endplate of the affected caudal vertebral body. The location of the center of rotation and the flexion radius correspond to the natural joint guidance in the vertebral joints. The physiological range of motion in regard to flexion/extension and lateral bending is restored. The axial rotation is limited only by the anatomical structures and not by the prosthesis. Pure translatory movements are not possible due to the ball and socket principle.



Flexion/extension

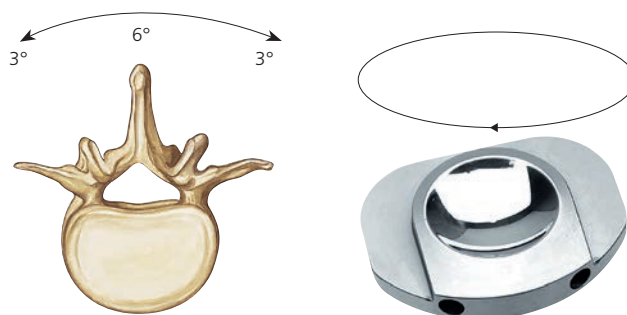


Lateral bending



¹ See White, Panjabi 1990; Percy, Portek, Shepard 1984; Percy, Tibrewal 1984; Dvorak et al 1991

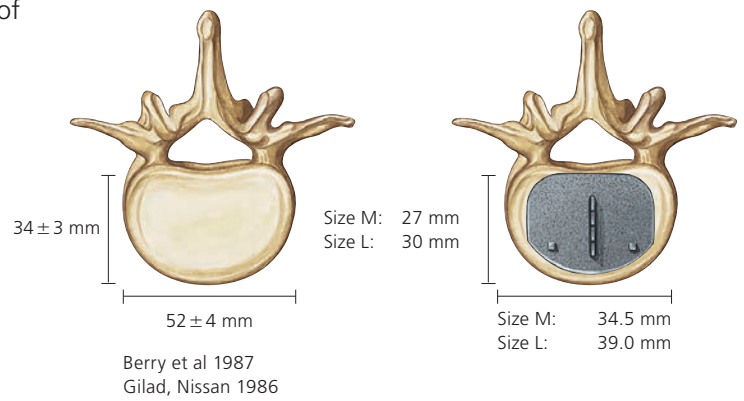
Axial rotation



IMPLANTS

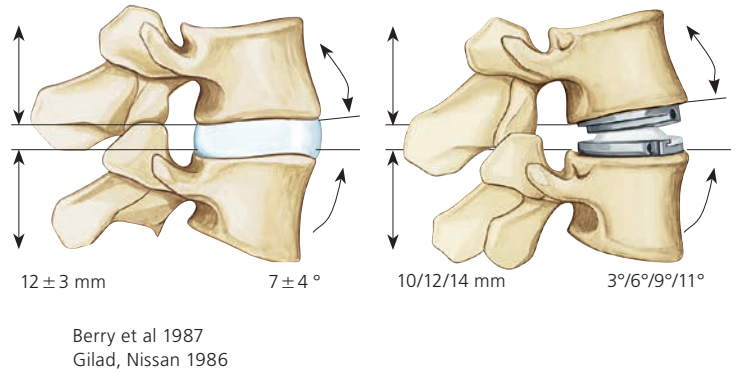
Two different sizes are available for optimal coverage of the vertebral endplates:


- M and L



The patient-specific intervertebral disc height and sagittal alignment of the affected segment can be restored thanks to:

- three different heights (10, 12 and 14 mm)
- four lordosis angles (3°, 6°, 9° and 11°)





prodisc L, uncemented

		M	L
Superior plates	3°	SSX660K	SSX670K
	6°	SSX520K	SSX540K
	11°	SSX522K	SSX542K
Inferior plates	0°	SSX524K	SSX544K
	3°	SSX662K	SSX672K
	8°	SSX664K	SSX674K
PE-inlays	10 mm	SSX626	SSX646
	12 mm	SSX627	SSX647
	14 mm	SSX628	SSX648

Note: Please observe the recommendations for the application of the different lordosis angles (page 22).

INSTRUMENTS

The **prodisc L** instrument set has been developed for minimally invasive, endoscopic or microscopic procedures.

Discectomy and mobilization

SFW580R Elevator



SFW650R **prodisc L** Spreader Forceps, curved



Trial implant system

24 trial implants correspond to the possible implant combinations.



Trial implant M, 3°

Art. no.	Height
SFW751R	10 mm
SFW752R	12 mm
SFW753R	14 mm

Trial implant M, 6°

Art. no.	Height
SFW651R	10 mm
SFW652R	12 mm
SFW653R	14 mm

Trial implant M, 9°

Art. no.	Height
SFW754R	10 mm
SFW755R	12 mm
SFW756R	14 mm

Trial implant M, 11°

Art. no.	Height
SFW654R	10 mm
SFW655R	12 mm
SFW656R	14 mm

Trial implant L, 3°

Art. no.	Height
SFW757R	10 mm
SFW758R	12 mm
SFW759R	14 mm

Trial implant L, 6°

Art. no.	Height
SFW657R	10 mm
SFW658R	12 mm
SFW659R	14 mm

Trial implant L, 9°

Art. no.	Height
SFW760R	10 mm
SFW761R	12 mm
SFW762R	14 mm

Trial implant L, 11°


Art. no.	Height
SFW660R	10 mm
SFW661R	12 mm
SFW662R	14 mm

SFW601R Adjustable Stop

The adjustable stop is attached to the trial implant to prevent excessive posterior positioning.



SFW565R Handle for Trial Implants



SFW602R Screwdriver for Adjustable Stop



Chisel instruments

Chisel, slotted

Art. no.	Height
SFW867R	10 mm
SFW868R	12 mm
SFW869R	14 mm



SFW691R Combined Hammer



Instruments for implant insertion

Inserter

Art. no.	Size
SFW672R	M
SFW673R	L



This multifunctional instrument is used for inserting the two implant plates, distracting the intervertebral space and inserting the PE-Inlay into the inferior plate.

SFW582R Lever, for Insertion Instruments



Distractor

Art. no.	Height
SFW874R	10 mm
SFW875R	12 mm
SFW876R	14 mm



Used to distract the inserter arms

Inserters for PE-Inlay




Art. no.	Size
SFW577R	M
SFW578R	L




Used to push PE-Inlay into inferior plate

Sets

SFW784R Vario Case for Prodisc-L Instruments



SFW785R Vario Case for Prodisc-L Trial Implants



OPTIONAL INSTRUMENTS

Struts

straight

Art. no.	Dimensions
SFW521	Height 10 mm, 6°, length 150 mm
SFW522	Height 12 mm, 6°, length 150 mm
SFW531	Height 10 mm, 6°, length 170 mm
SFW532	Height 12 mm, 6°, length 170 mm
SFW541	Height 10 mm, 6°, length 190 mm
SFW542	Height 12 mm, 6°, length 190 mm



angled

Art. no.	Dimensions
SFW621	Height 10 mm, 6°, length 150 mm
SFW622	Height 12 mm, 6°, length 150 mm
SFW631	Height 10 mm, 6°, length 170 mm
SFW632	Height 12 mm, 6°, length 170 mm
SFW641	Height 10 mm, 6°, length 190 mm
SFW642	Height 12 mm, 6°, length 190 mm


388.140 Socket Wrench Ø 6.0 mm,
with straight handle

SFW520 Handle for Strut

SFW788R Vario Case for prodisc L Struts

The prodisc L struts hold the disc segment open and facilitate the discectomy procedure and the insertion of the prosthesis. The struts can be secured to the SynFrame.

Note: The struts should never be used to spread the segment, only to hold open a segment that has already been mobilized. The struts are positioned upright into the intervertebral disc space without applying any force while the intervertebral disc space is held open by the spreader forceps (SFW650R).



Chisels with non-slotted blades

Art. no.	Height
SFW567R	10 mm
SFW568R	12 mm
SFW569R	14 mm



Spreader Forceps, straight

Art. no.
SFW550R



Wing Nut for Distractors

Art. no.
SFW893R



The wing nuts allow the distractors to be used with both hands.

Revision Set

An indicated instrument set is available for any revisions to the **prodisc L** (68.820.100). Please contact your Centinel Spine representative.

OTHER CENTINEL SPINE PRODUCTS FOR ACCESS, DISCECTOMY AND ENDPLATE PREPARATION

SynFrame. Modular approach and retraction system for minimally invasive surgery.

Set

01.609.102 Set SynFrame RL, lumbar
187.310 SynFrame Basic System in Vario Case

Information material

036.000.066 SynFrame, Flyer
036.000.695 SynFrame RL, Flyer



The SynFrame System is a modular approach and retraction system consisting of a basic system (basic construction) and modules specially designed for specific requirements and applications of various indications and/or approach techniques. The structure of the SynFrame basic system is always in the same sequence and according to the same principles. SynFrame RL lumbar is an additional module for the approach and retraction system SynFrame. It includes radiolucent soft tissue and muscle retractors and semi-transparent bone levers for minimally invasive procedures.

SynFrame-RL. Radiolucent retractors

The radiolucent components (retractors and bone levels) allow the relevant parts to be constantly visible during **prodisc** surgery.

Information material

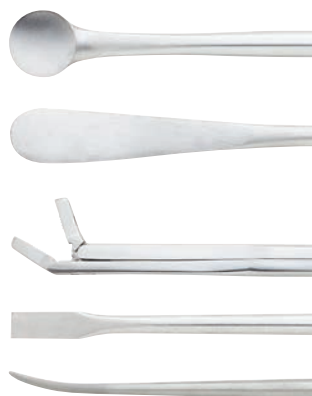Art. no.	Title
036.000.066	SynFrame, Flyer
036.000.695	SynFrame-RL, Flyer



Proprep. Intervertebral disc preparation set for anterior lumbar surgery.

Information material

Art. no.	Title
036.000.760	Proprep, Flyer



Electric Pen Drive and Air Pen Drive. Compact drive units with specific attachments for a wide range of applications. A specific attachment is available for endplate preparation (05.001.055).

Information material

Art. no.	Title
036.000.800	E-Pen Drive, Instructions for Use
036.000.503	Air Pen Drive, Instructions for Use



Optimized attachment to prepare the endplate for Pro-disc insertion.



For further information please contact your local Centinel Spine representative.

PREOPERATIVE PLANNING

Recommendation on the application of the various lordosis angles

If the patient is in an upright position, the PE-inlay should always be placed in as horizontal a position as possible. It is essential to ensure that the PE-inlay is not inclined in a posterior direction.

The following recommendations apply to most cases:

L5/S1

Inferior plates with lordosis angles should be selected for L5/S1 if the angle between the horizontal (for upright patients) and the S1 endplates is at least 15°.

Examples: A combination of 3° superior plate and 3° inferior plate for a segmental lordosis of 6°, or a combination of 3° superior plate and 8° inferior plate for a segmental lordosis of 11°.

L4/L5 and higher

Inferior plates without a lordosis angle (0°) should generally be used for L4/L5 segments and higher.

A prosthesis with a 3° lordosis angle (combination of 3° superior plate and 0° inferior plate) should only be used in segments with a segmental lordosis of close to 0°.

Note: Only implants with a total lordosis angle (3°, 6°, 9° and 11°) represented by a trial implant may be implanted.

Note: In order to minimize the risk of atraumatic periprosthetic vertebral fractures, surgeons must consider all co-morbidities, past and present medications, previous treatments, etc. Upon reviewing all relevant information the surgeon must determine whether a bone density scan is prudent. A screening questionnaire, SCORE (Simple Calculated Osteoporosis Risk Estimation) may be used to screen patients if a DEXA is performed, exclusion from receiving the device should be considered if the DEXA bone density measured T-score is < -1.0 as this patient may be osteoporotic.

SURGICAL TECHNIQUE

1

Approach

Expose the intervertebral disc and the adjacent vertebral bodies through the anterior approach to the lumbar spine. The approach can either be transperitoneal or retroperitoneal. Identify and mark the midline with the image intensifier.

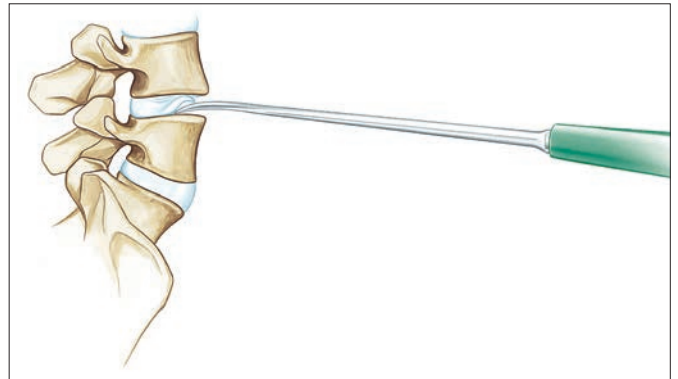
2

Discectomy

Required instrument

SFW580R Elevator

Carefully clean out the intervertebral space with the elevator and remove the intervertebral disc tissue and cartilage fragments from the endplates.



3

Mobilize segment

Required instruments

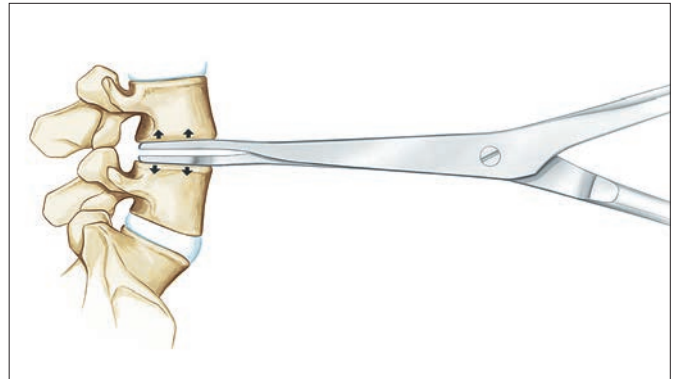
SFW550R Spreader Forceps, straight

SFW650R Spreader Forceps, curved

Prior to distraction ensure that the position of the spreader forceps posterior is adequately deep. Check the lateral position using the image intensifier.

Distract the intervertebral space with the spreader forceps in a parallel manner to restore the height and to enable access to the posterior part.

Note: An essential prerequisite for a satisfactory clinical result is good mobilization. Insufficient mobilization can also result in an overload of the insertion instruments.



4**Insert the trial implant****Required instruments**

Trial implant

SFW565R Handle for Trial Implants

SFW601R Adjustable Stop

SFW602R Screwdriver for Adjustable Stop

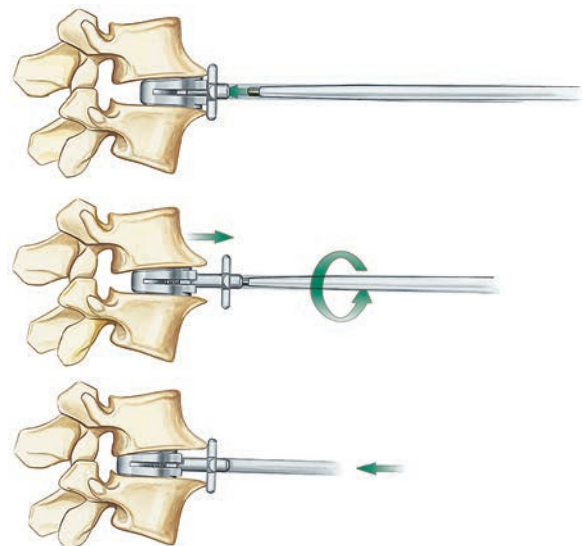
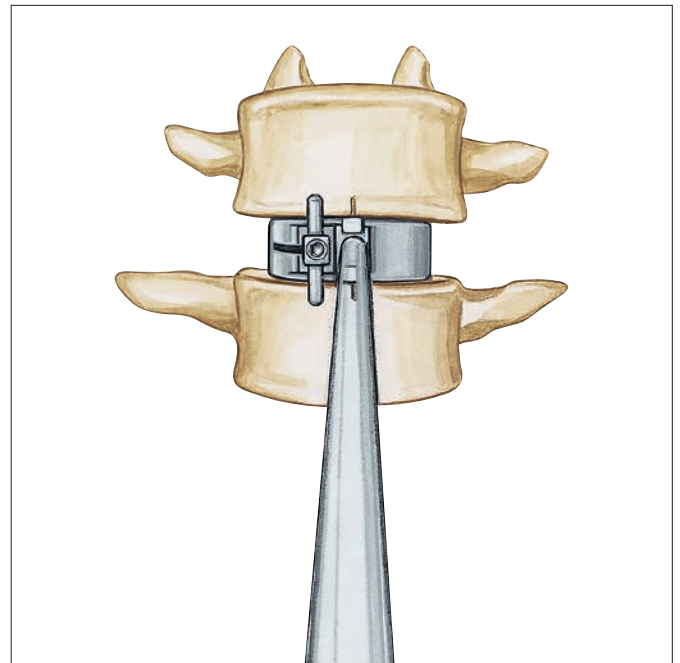
SFW691R Combined Hammer

Determine the final size, height and lordosis angle and the position of the prosthesis. The aim is to select the largest possible footprint with the smallest necessary height.

- Align the trial implant with the midline; while monitoring the process on the image intensifier, carefully use the hammer to insert the trial implant into the intervertebral space to the rear edge of the endplate.

The trial implant should be lightly secured by the endplates of the adjacent vertebral bodies. If the implant is seated too loosely in the intervertebral space, select the next highest size. Check the position of the trial implant using the image intensifier, both from an AP perspective as well as laterally.

Note: The trial implant can be optimally positioned with the aid of the adjustable stop to prevent the implant from being inserted too far into the intervertebral space. If the trial implant must be positioned more deeply, the stop can be adjusted using the screwdriver. One 360° rotation equals 1 mm.



5

Chiseling

Required instruments

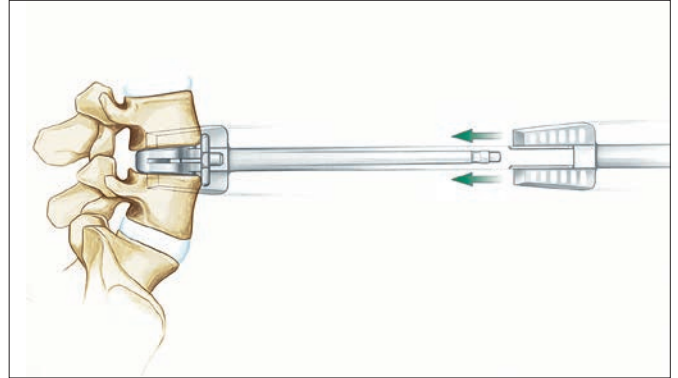
SFW867R	Chisel, 10 mm
SFW868R	Chisel, 12 mm
SFW869R	Chisel, 14 mm
SFW691R	Combined Hammer

Guide the chisel over the shaft of the trial implant and create the keel bed for the prosthesis.

The selected trial implant serves as a guide for the chisel and sets the direction and chisel depth.

The chisel cut determines the final implant position and must therefore be checked with the image intensifier.

Precaution: Heterotopic ossification (HO) is a possible cause for fusion of the treated segment. Copious saline lavage is recommended to remove osteogenic stimuli (blood/bone marrow). HO might be reduced when bone wax is used to close cavities in the bone (screw holes) and open bone surfaces after removal of anterior osteophytes¹.



¹ See Barbagallo 2014

6**Insert the implant plates****Required instruments**

SFW672R Inserter

SFW673R

SFW691R Combined Hammer

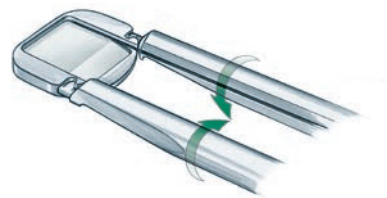
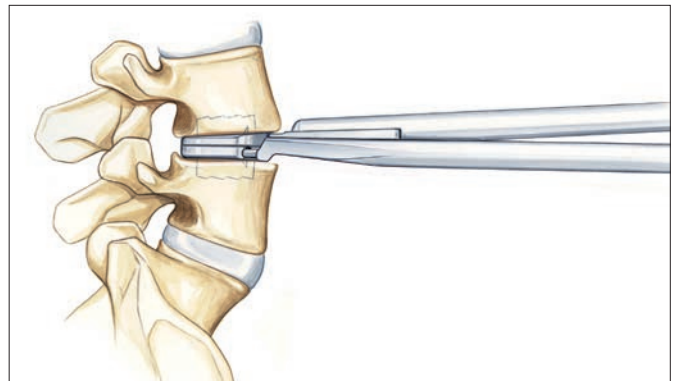
Place the top and bottom implant plates on the inserter. Lock the bottom plate by turning the inserter arms. Using the chisel cuts as a guide, insert the implant plates into the intervertebral space.

- Check the final position of the implant using the image intensifier, both from an AP perspective as well as laterally.

Note: This step is done without distraction so as not to damage tissues, longitudinal ligaments and nerve roots.

Note: Do not attempt to force and lock the polyethylene inlay if the end plates have not separated. Additional discectomy and remobilization may be required if the end plates do not separate.

Note: The prodisc L implants are not designed to be used with bone cement.



7

Insert the PE-inlay

Required instruments

SFW874R	Distractor 10 mm
SFW875R	Distractor 12 mm
SFW876R	Distractor 14 mm
SFW577R	Inserter for PE-Inlay, M
SFW578R	Inserter for PE-Inlay, L

Lay the PE-Inlay as shown on the instrument (“dome up”) in the slot of the inserter. Use the distractor corresponding to the selected implant height and attach it to the inserter.

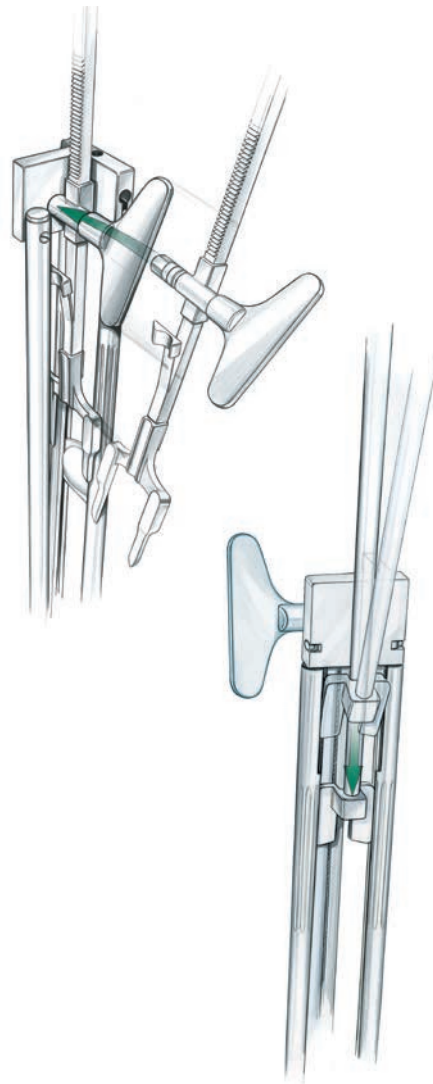
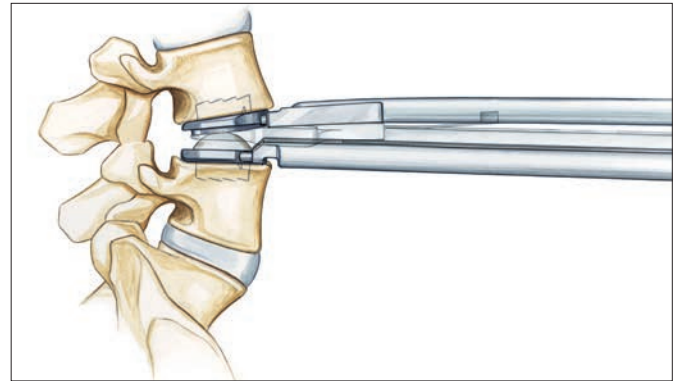
Use the wing nut to screw the distractor down to the mechanical stop. While distracting the segment the PE-Inlay is automatically brought into position along the slot.

Check the distance between the implant plates using the image intensifier. There should be a visible radiolucent space between the metal plates.

Using the inserter, insert the PE-Inlay into the bottom plate of the implant until it snaps into place.

Note: It is crucial to check visually and manually if the PE-inlay is securely locked into the inferior implant plate (“no step, no gap”).

- Check the final position of the prosthesis using the image intensifier.



8

Remove instruments


Required instruments

SFW691R Combined Hammer

SFW582R Lever for Insertion Instruments

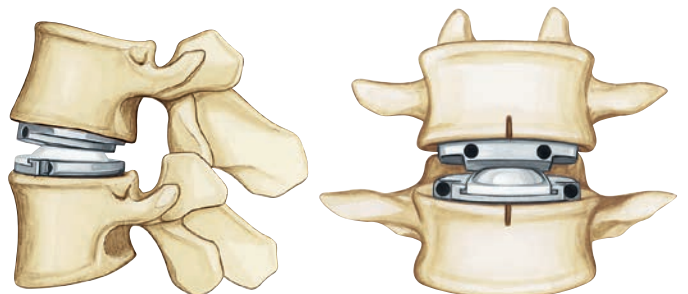
Unlock the inferior plate by turning the arms outwards. Using a slide hammer, pull the inserter straight back and remove from the operative field.

Note: The use of a lever for insertion instruments can facilitate the rotation of the distractor arms.



The implant is now – oriented on the midline – securely seated on the cortical ring of the vertebral body.

- Check the final position of the implant using the image intensifier, both from an AP perspective as well as laterally.



Multisegmental procedures

Perform multisegmental operations one segment at a time.

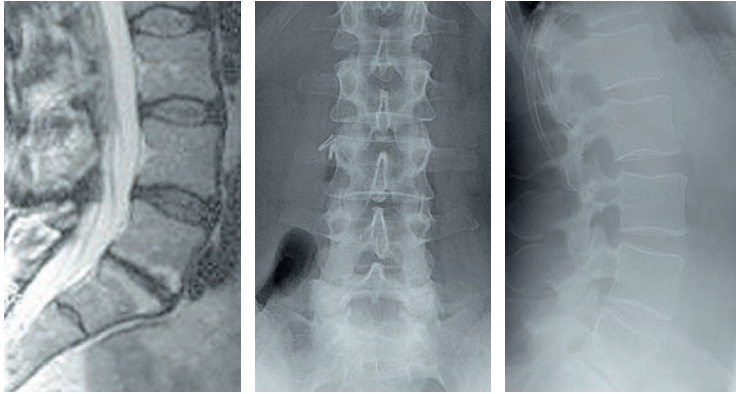
All instruments must be removed from the treated segment before the next affected segment can be exposed and cleaned out.

Follow steps 2–8 as described above.

Note: In the case of multisegmental surgery, always start with the segment that is most severely collapsed.

CASE 1: DEGENERATIVE DISC DISEASE L5/S1

Preoperative

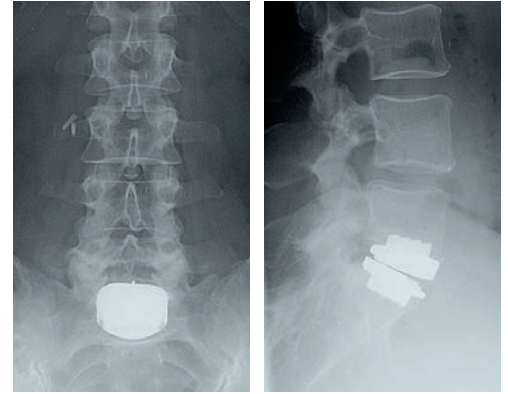


MRI lateral

Anteroposterior

Lateral

Postoperative



Anteroposterior

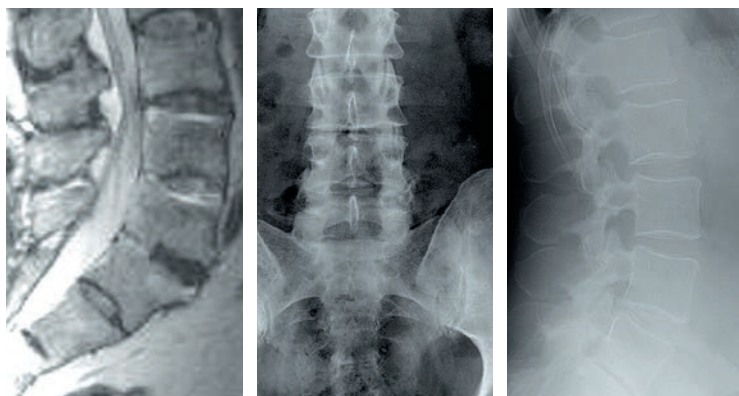
Lateral

Patient: Female, 56 years of age
Symptoms: Continuous, severe pain in the lower back
Diagnosis: Back pain arising from an intervertebral disc in the lumbar region L5/S1
Segmental instability
Herniated nucleus pulposus L5/S1
Signs of Modic change
Prior therapy: Unsuccessful conservative treatment (for more than 6 months)
Visual analogue scale:
Preoperative: 8.5

Postoperative: 3.0 (24 months after operation)
Satisfaction: Episodic back pain, completely satisfied with the treatment

CASE 2: DEGENERATIVE DISC DISEASE L3/L4 AND L4/L5

Preoperative



MRI lateral

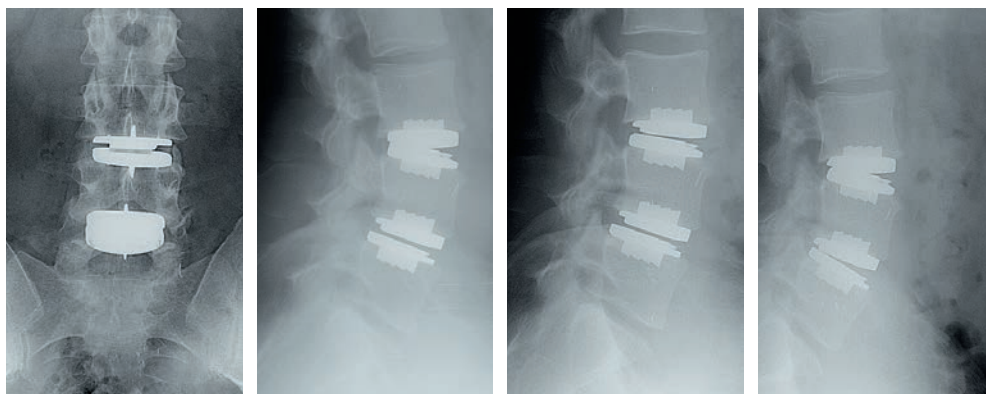
Anteroposterior

Lateral

Patient: Male, 47 years of age
Symptoms: Continuous, severe pain in the lower back
Diagnosis: Back pain arising from an intervertebral disc in the lumbar region L3–L5
Segmental instability of L3–L5
modic signs
Prior therapy: Unsuccessful spinal surgery (for more than 6 months)
Visual analogue scale:
Preoperative: 8.0

Postoperative: 0.0 (24 months after operation)
Satisfaction: No back pain, completely satisfied with the treatment

Postoperative



Anteroposterior

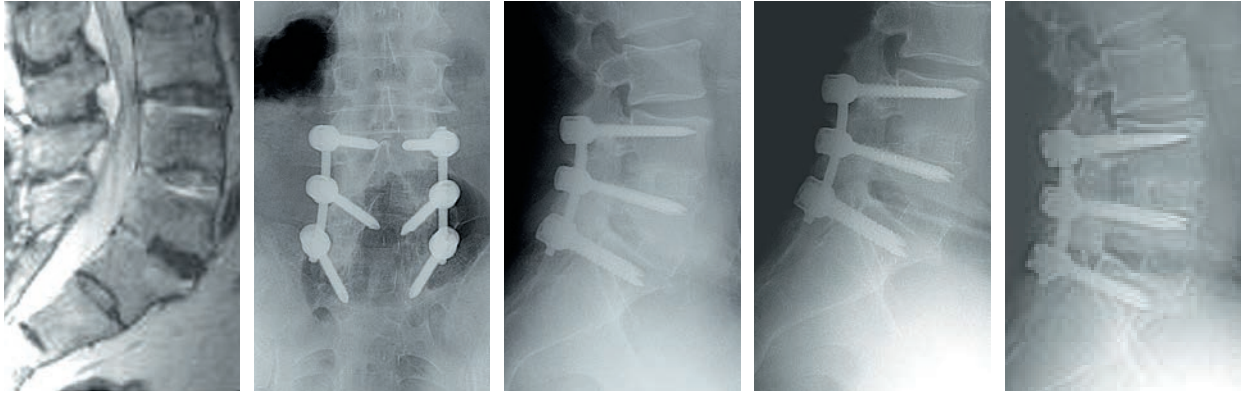
Lateral

Lateral flexion

Lateral extension

CASE 3: DEGENERATIVE DISC DISEASE L3/L4 – FUSED SEGMENTS L4–S1

Preoperative



MRI lateral

Anteroposterior

Lateral

Lateral flexion

Lateral extension

Patient:

Male, 57 years of age

Symptoms:

Continuous, severe pain in the lower back

Diagnosis:

Back pain arising from an intervertebral disc in the lumbar region L3/L4

Segmental instability at L3/L4 neighbouring fusion of L4–S1

Secondary spinal stenosis L3/L4

Prior therapy:

Unsuccessful conservative treatment (for more than 6 months)

Visual analogue scale:



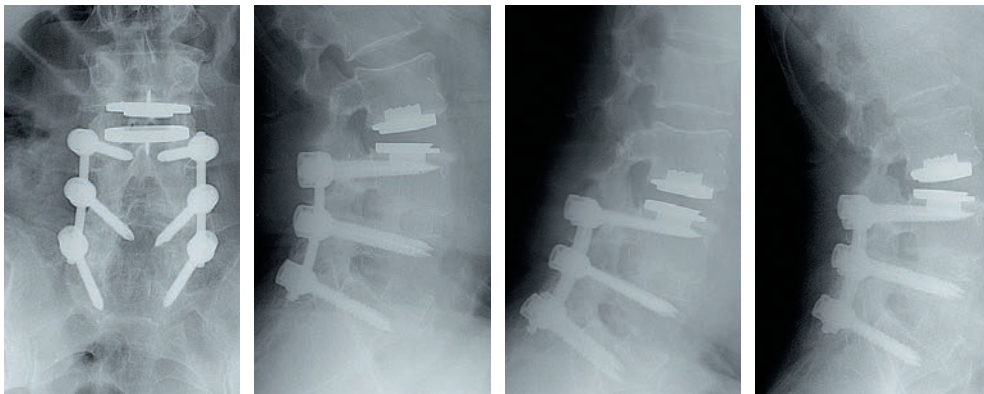
Preoperative: 6.2



Postoperative: 1.0 (24 months after operation)

Satisfaction: No back pain, completely satisfied with the treatment

Postoperative



Anteroposterior

Lateral

Lateral flexion

Lateral extension

BIBLIOGRAPHY

- Bae H, Kanim LEA, Sra P, Delamarter R, Kropf M (2004) Prodisc lumbar disc replacement vs fusion: preservation of motion and patient self assessment at 1-to-2-year follow up. *Spine J*: 4 (5): 12
- Barbagallo G.M.V., Certo F, Visocchi M, Sciacca G, Albanese V (2014) Double-level cervical total disc replacement for adjacent segment disease: is it a useful treatment? Description of late onset heterotopic ossification and review of the literature. *Eur Rev Med Pharmacol Sci* 18 (1): 15-23
- Berry JL, Moran JM, Berg WS, Steffee AD (1987) A morphometric study of the human lumbar and selected thoracic vertebrae. *Spine* 12 (4): 362–367
- Bertagnoli R, Kumar S (2002) Indications for full prosthetic disc arthroplasty: a correlation of clinical outcome against a variety of indications. *Eur Spine J* 11 (2): 131–136
- Bertagnoli R, Marnay T, Mayer HM (2005) Total Disc Replacement for degenerative disc disease in the lumbar spine. 2nd ed. Synthes, Oberdorf
- Delamarter RB, Fribourg DM, Kanim LE, Bae H (2003) Prodisc® Artificial Total Lumbar Disc Replacement: Introduction and Early Results from the United States Clinical Trial. *Spine* 28: 167–175
- Dvorak J, Panjabi MM, Chang DG, Theiler R, Grob D (1991) Functional Radiographic Diagnosis of the Lumbar Spine – Flexion-Extension and Lateral Bending. *Spine* 16 (5): 562–571
- Dvorak J, Vajda EG, Grob D, Panjabi MM (1995): Normal motion of the lumbar spine as related to age and gender. *Eur Spine J* 4: 18–23
- Gilad I, Nissan M (1986) A study of Vertebra and Disc Geometric Relations of the Human Cervical and Lumbar Spine. *Spine* 11 (2): 154–157
- Han JS, Goel VK, Ahn JY, Winterbottom J, McGowan D, Weinstein J, Cook T (1995): Loads in the spinal structures during lifting: development of a three-dimensional comprehensive biomechanical model. *Eur Spine J* 4 (3): 153–168
- Huang RC, Girardi FP, Cammisa FP, Tropiano P, Marnay T (2003) Long-Term Flexion-Extension Range of Motion of the Prodisc® Total Disc Replacement. *J Spinal Disord Tech* 16 (5): 435–440
- Louis R (1982): *Chirurgie du Rachis: Anatomie Chirurgicale et Voies d'Abord*. Berlin, Springer
- Mayer HM, Korge A (2002) Non-fusion technology in degenerative lumbar spinal disorders: facts, questions, challenges. *Eur Spine J* 11: 85–91
- Mayer HM, Wiechert K, Korge A, Qose I (2002) Minimally invasive total disc replacement: surgical technique and preliminary clinical results. *Eur Spine J* 11: 124–130
- Mayer HM, Wiechert K (2002) Microsurgical anterior approaches to the lumbar spine for interbody fusion and total disc replacement. *Neurosurgery* 51: 159–165
- Pearcy MJ, Portek I, Shepard J (1984) Three-Dimensional X-ray Analysis of Normal Movement in the Lumbar Spine. *Spine* 9 (3): 294–297
- Pearcy MJ, Tibrewal SB (1984) Axial Rotation and Lateral Bending in the Normal Lumbar Spine Measured by Three-Dimensional Radiography. *Spine* 9 (6): 582–591
- Szpalski M, Gunzburg R, Mayer HM (2002) Spine arthroplasty: a historical review. *Eur Spine J* 11: 65–84
- Tropiano P, Huang RC, Girardi FP, Marnay T (2003) Lumbar disc replacement: preliminary results with Prodisc® II after minimum follow-up period of 1 year. *J Spinal Disord Tech* 16 (4): 362–368
- Tropiano P, Huang RC, Girardi FP, Cammisa FP, Marnay T (2005) Lumbar total disc replacement. Seven to Eleven-Year Follow-Up. *J Bone Joint Surg Am*: 490–496
- White AA, Panjabi MM (1990): *Clinical biomechanics of the spine*. Philadelphia, Lippincott.
- Yue J, Bertagnoli R, Husted D, Shah R, Kershaw T (2004) The treatment of disabling multilevel lumbar discogenic low back pain with total disc arthroplasty utilizing the prodisc prosthesis: a prospective study with 2-year minimum follow up. *Spine J* 4 (5): 49–50

Zigler JE, Clinical Results with Prodisc® (2003) European Experience and U.S. Investigation Device Exemption Study. *Spine* 28: 163–166

Zigler JE, Burd TA, Vialle EN, Sachs BL, Rashbaum RF, Ohnmeiss DD (2003) Lumbar spine arthroplasty: early results using the Prodisc® II: a prospective randomized trial of arthroplasty versus fusion. *J Spinal Disord Tech* 16 (4): 352–361

Zigler J, Sachs B, Rashbaum R, Ohnmeiss D (2004) Total disc replacement using ProDisc 12-to-24-month follow up results of a prospective randomized comparison to fusion. *Spine J* 4 (5): 25–26

Zigler JE (2004) Lumbar Spine Arthroplasty using the Prodisc® II. *Spine J* 4 (6): 260–267



CENTINEL SPINE, LLC

900 Airport Road, Suite 3B
West Chester, PA 19380
Tel: 484.887.8810
Fax: 800.493.0966
cs@centinelspine.com
www.centinelspine.com

EMEA OFFICE
Grafenauweg 8,
6300 Zug, Switzerland

© 2019 Centinel Spine, LLC or its affiliates. All rights reserved.

Centinel Spine® is a registered trademark of Centinel Spine, LLC.

LBL430 Rev 4 (10/2020)

This publication is not intended for distribution in the USA. Not all products are currently available in all markets.

CE
2797